



# Concurrent Hybrid Coronary Revascularization Procedure for Multi-vessel Coronary Artery Disease in a Hybrid Operation Room

Yu-Jen Chen, M.D.<sup>a,b,c</sup>, Yung-Kuo Lin, M.D., Ph.D.<sup>a,b</sup>, Shao-Jung Li, M.D., Ph.D.<sup>d,e,f,g</sup>,  
Ming-Hsiung Hsieh, M.D.<sup>a,b</sup>

<sup>a</sup>*Division of Cardiovascular Medicine, Department of Internal Medicine, Wan Fang Hospital,  
Taipei Medical University, Taipei, Taiwan*

<sup>b</sup>*Division of Cardiology, Department of Internal Medicine, School of Medicine, College of Medicine,  
Taipei Medical University, Taipei, Taiwan*

<sup>c</sup>*Institute of Public Health, National Yang-Ming University, Taipei, Taiwan*

<sup>d</sup>*Department of Surgery, School of Medicine, College of Medicine, Taipei Medical University, Taipei, Taiwan*

<sup>e</sup>*Division of Cardiovascular Surgery, Department of Surgery, Wan Fang Hospital,  
Taipei Medical University, Taipei, Taiwan*

<sup>f</sup>*Cardiovascular Research Center, Wan Fang Hospital, Taipei Medical University, Taipei, Taiwan*

<sup>g</sup>*Taipei Heart Institute, Taipei Medical University, Taipei, Taiwan*

## Abstract

Coronary artery bypass grafting and percutaneous coronary intervention are traditionally considered isolated treatment options for patients with coronary artery disease. A hybrid approach, including bypass surgery plus coronary stenting, may take advantage of the benefits of both treatment methods for particularly stenotic lesions. Hybrid coronary revascularization, combining a minimally invasive surgery using internal mammary artery to left anterior descending artery anastomosis and coronary intervention for remaining lesions, can be performed in one sitting (concurrent) or separately (staged). Whether concurrent or staged hybrid procedure is the better strategy remains to be elucidated. We here report on a patient with multi-vessel coronary artery disease who underwent a concurrent hybrid procedure in a hybrid operation room.

**Keywords:** hybrid procedure, coronary revascularization, multiple vessel disease

## Introduction

In patients with multi-vessel coronary artery disease (CAD) involving proximal stenosis of the left anterior descending coronary artery (LAD), coronary artery bypass grafting (CABG)

more often provides better revascularization than percutaneous coronary intervention (PCI) which is recommended only in those with a SYNTAX score  $\leq 22$ .<sup>1</sup> While CABG is associated with a decrease in repeat revascularization compared to PCI, it is a highly invasive procedure associated

**Address for correspondence:** Ming-Hsiung Hsieh, M.D.

No.111, Sec. 3, Xinglong Rd., Wenshan Dist., Taipei City 116, Taiwan

Tel: +886-2-2930-7930; Fax: +886-2-8662-1135; E-mail: mhhsieh@tmu.edu.tw



with a greater risk of peri-procedural stroke.<sup>2</sup> By comparison, PCI is less invasive but yields suboptimal results in patients with multi-vessel disease, particularly those with diabetes and higher coronary complexity.<sup>3</sup>

With advances in technique and technology, important comparative effectiveness trials have focused on the durability of surgical arterial grafts and the decreasing invasiveness of coronary revascularization over the past 2 decades. Given the superiority of CABG compared to PCI, which can be attributed to the use of internal mammary artery (IMA) to LAD anastomosis, hybrid coronary revascularization (HCR) procedure was introduced in 2011 by the American Heart Association/American College of Cardiology Foundation's updated guidelines for CABG surgery.<sup>4</sup> HCR combines minimally invasive bypass surgery to the LAD with PCI deploying drug-eluting stents (DES) at non-LAD vessels,<sup>5</sup> and it provides the patient with potential benefits beyond CABG or PCI alone while decreasing the complications associated with each individual procedure.

The components of HCR can be performed at different times (staged) or at the same time (concurrent). While most studies have included patients receiving staged HCR, the advantages of concurrent HCR procedure have been less noticed. We here present a patient with multi-vessel CAD who underwent a concurrent HCR procedure in a hybrid operation room (OR).

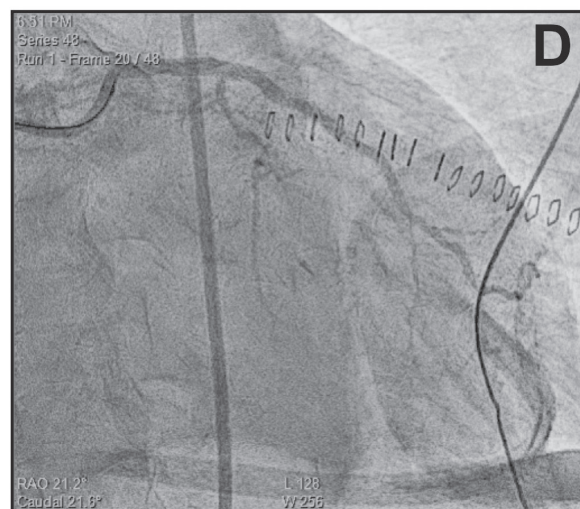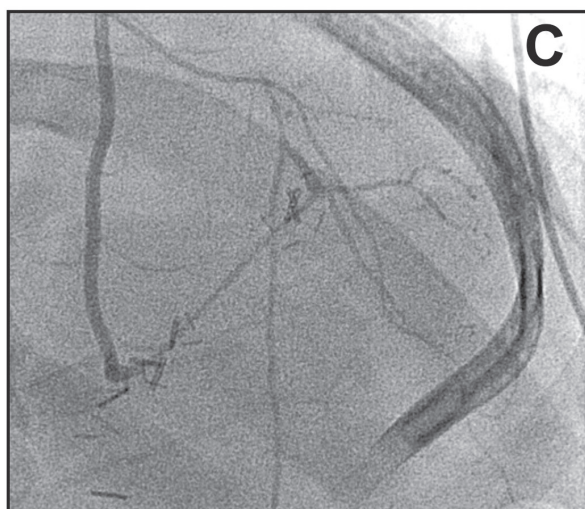
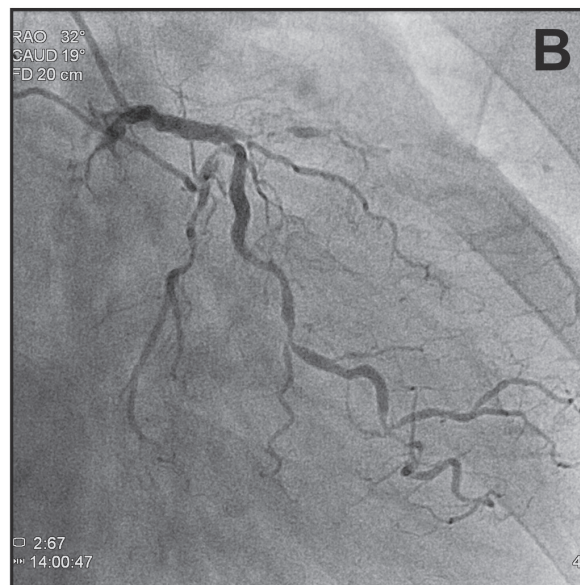
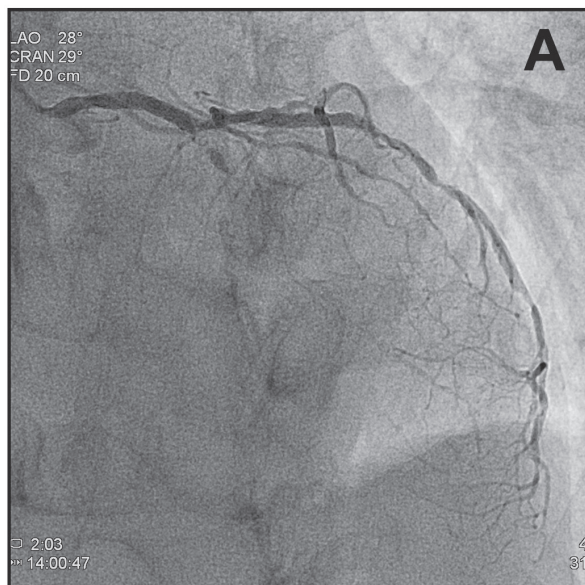
## Case Report

A 65-year-old smoking male with a history of hypertension and type 2 diabetes mellitus presented with refractory heart failure. He was diagnosed with multi-vessel CAD, and CABG was recommended because of his low left ventricular ejection fraction (LVEF) of 38%. He was referred to our hospital for surgical intervention. Since most studies have suggested that HCR is non-inferior to CABG in terms of short-term outcomes, including myocardial

infarction, stroke, or death, the patient opted for a concurrent HCR procedure by means of shared decision making. The angiogram was evaluated in view of a concurrent hybrid procedure, and it showed left main coronary artery (LMCA) stenosis and distal LMCA lesion extending to the LAD and the left circumflex artery (LCX) (Medina 1.1.1). Together, the right coronary artery (RCA) and the LCX constituted a network of collateral circulation to the LAD (Figure 1A and 1B). The patient underwent off-pump minimally invasive direct coronary artery bypass (MIDCAB) using an approach through the left IMA to the LAD via left mini thoracotomy through the 5<sup>th</sup> intercostal space (Figure 1C). The use of aspirin was uninterrupted perioperatively and a loading dose of thienopyridines (clopidogrel 300 mg) was given immediately before PCI. Then concurrent PCI for the LMCA to LCX lesion was performed with a DES (Figure 1D). The patient recovered well and was extubated at the second day. He was discharged from hospital 5 days after the concurrent HCR procedure, with LVEF recovered to 56% at a 3-month follow-up.

## Discussion

CABG and PCI revascularization are traditionally considered isolated options. HCR allows an opportunity to better match the best strategy for multi-vessel CAD. While HCR can be conducted as staged or concurrent, there has been little study to shed light on the differences between these two strategies. Harskamp et al. suggested there were no differences in hospital deaths, myocardial infarction, stroke, and repeat revascularization in staged versus concurrent HCR procedures, but only three studies using the concurrent procedure were included.<sup>6</sup> Although staged HCR is the most frequently used approach, there are some limitations and risks of concern for us. Our patient was offered a feasible option of concurrent HCR procedure without increased bleeding risk which was accomplished with acceptable clinical outcome.



**Figure 1A and 1B.** The angiogram prior to intervention shows left main coronary artery (LMCA) stenosis and distal LMCA lesion that extends to the left anterior descending artery (LAD) and the left circumflex artery (LCX) (Medina 1.1.1).

**Figure 1C.** The angiogram after minimally invasive direct coronary artery bypass shows the completion of left internal mammary artery anastomosis to the LAD.

**Figure 1D.** The angiogram after intervention shows concurrent percutaneous coronary intervention for the LMCA to the LCX with a drug eluting stent.

Staged HCR can be performed in two different ways: surgery followed by PCI or PCI followed by surgery. Surgery followed by PCI is the most frequent approach given the fact that dual antiplatelet therapy (DAPT) can be

administered after anastomosis completion. This approach may reduce the bleeding risk and allow more aggressive use of DAPT in preventing stent thrombosis.<sup>7</sup> However, it leaves non-LAD regions in a suboptimally perfused status before





PCI, and it requires knowledge, experience, and capacity of surgeons to effectively deal with the crux of the issue.<sup>8</sup> By comparison, PCI followed by surgery remains useful in patients with acute coronary syndrome who need an emergency revascularization to non-LAD territory, but this approach may increase risk of bleeding during subsequent surgery. The interruption of DAPT prior to surgery is associated with an increased risk of stent thrombosis or myocardial infarction.<sup>8</sup>

Concurrent HCR procedures are performed in a fully equipped hybrid OR, so we have the ability to switch to open surgery when handling complications that may arise. Angiography can be performed immediately upon completion of the LIMA anastomosis to assure the quality of the anastomosis and permit revision if needed.<sup>9</sup> DAPT can be administered after the surgical portion of HCR, minimizing both risks of bleeding and stent thrombosis. In contrast to staged HCR, which, regardless of the order of the procedures needs 2 procedures and 2 hand-offs,<sup>10</sup> concurrent HCR reduces exposure to contrast and anesthetic, and provides a shorter length of stay and higher patient satisfaction.<sup>11</sup>

With concurrent HCR emerging as a treatment strategy in patients with multi-vessel CAD, a health economic analysis and evaluation comparing with traditional CABG is essential for prioritizing scarce healthcare resources. Although concurrent HCR consumes more hospital resources than conventional CABG, studies have demonstrated a significant decrease in postoperative costs as a result of a shorter length of stay in hospital.<sup>12</sup> Rimestad et al. reported less impairment of normal activities early after concurrent HCR compared to conventional CABG, suggesting patients might return to work earlier.<sup>13</sup>

In conclusion, the role of HCR is expected to grow especially in the aging population with multiple comorbidities. Although current evidence suggests no differences in short-term outcomes whether after staged or concurrent procedures, the concurrent HCR may shorten length of stay and

minimize bleeding risk. We reported a successful concurrent HCR procedure on a patient with multi-vessel CAD in a hybrid OR.

## References

1. Neumann FJ, Sousa-Uva M, Ahlsson A, et al. 2018 ESC/EACTS Guidelines on myocardial revascularization. *Eur Heart J* 2019;40:87-165.
2. Mack MJ, Head SJ, Holmes DR Jr., et al. Analysis of stroke occurring in the SYNTAX trial comparing coronary artery bypass surgery and percutaneous coronary intervention in the treatment of complex coronary artery disease. *JACC. Cardiovasc Interv* 2013;6:344-54.
3. Head SJ, Milojevic M, Daemen J, et al. Mortality after coronary artery bypass grafting versus percutaneous coronary intervention with stenting for coronary artery disease: a pooled analysis of individual patient data. *Lancet* 2018;391:939-48.
4. Hillis LD, Smith PK, Anderson JL, et al. 2011 ACCF/AHA Guideline for Coronary Artery Bypass Graft Surgery: a report of the American College of Cardiology Foundation/American Heart Association Task Force on Practice Guidelines. *Circulation* 2011;124:e652-735.
5. Reicher B, Poston RS, Mehra MR, et al. Simultaneous "hybrid" percutaneous coronary intervention and minimally invasive surgical bypass grafting: feasibility, safety, and clinical outcomes. *Am Heart J* 2008;155:661-7.
6. Harskamp RE, Bagai A, Halkos ME, et al. Clinical outcomes after hybrid coronary revascularization versus coronary artery bypass surgery: a meta-analysis of 1,190 patients. *Am Heart J* 2014;167:585-92.
7. Fihn SD, Gardin JM, Abrams J, et al. 2012 ACCF/AHA/ACP/AATS/PCNA/SCAI/STS Guideline for the diagnosis and management of patients with stable ischemic heart disease: a report of the American College of Cardiology Foundation/American Heart Association Task Force on Practice Guidelines, and the American College of Physicians, American Association for Thoracic Surgery, Preventive Cardiovascular Nurses Association, Society for Cardiovascular Angiography and Interventions, and Society of Thoracic Surgeons. *J Am Coll Cardiol* 2012;60:e44-e164.
8. Avgerinos DV, Charitakis K. Hybrid coronary revascularization: present and future. *Hellenic J Cardiol* 2015;56:193-6.
9. Hu FB, Cui LQ. Short-term clinical outcomes after



- hybrid coronary revascularization versus off-pump coronary artery bypass for the treatment of multivessel or left main coronary artery disease: a meta-analysis. *Coron Artery Dis* 2015;26:526-34.
10. Gosev I, Leacche M. Hybrid coronary revascularization: the future of coronary artery bypass surgery or an unfulfilled promise? *Circulation* 2014;130:869-71.
  11. Song Z, Shen L, Zheng Z, et al. One-stop hybrid coronary revascularization versus off-pump coronary artery bypass in patients with diabetes mellitus. *J Thoracic Cardiovasc Sur* 2016;151:1695-1701.
  12. Bachinsky WB, Abdelsalam M, Boga G, Kiljanek L, Mumtaz M, McCarty C. Comparative study of same sitting hybrid coronary artery revascularization versus off-pump coronary artery bypass in multivessel coronary artery disease. *J Interv Cardiol* 2012;25:460-8.
  13. Rimestad JM, Christiansen EH, Modrau IS. One-year cost-effectiveness and safety of simultaneous hybrid coronary revascularization versus conventional coronary artery bypass grafting. *Interact Cardiovasc Thoracic Surg* 2019;29:217-23.