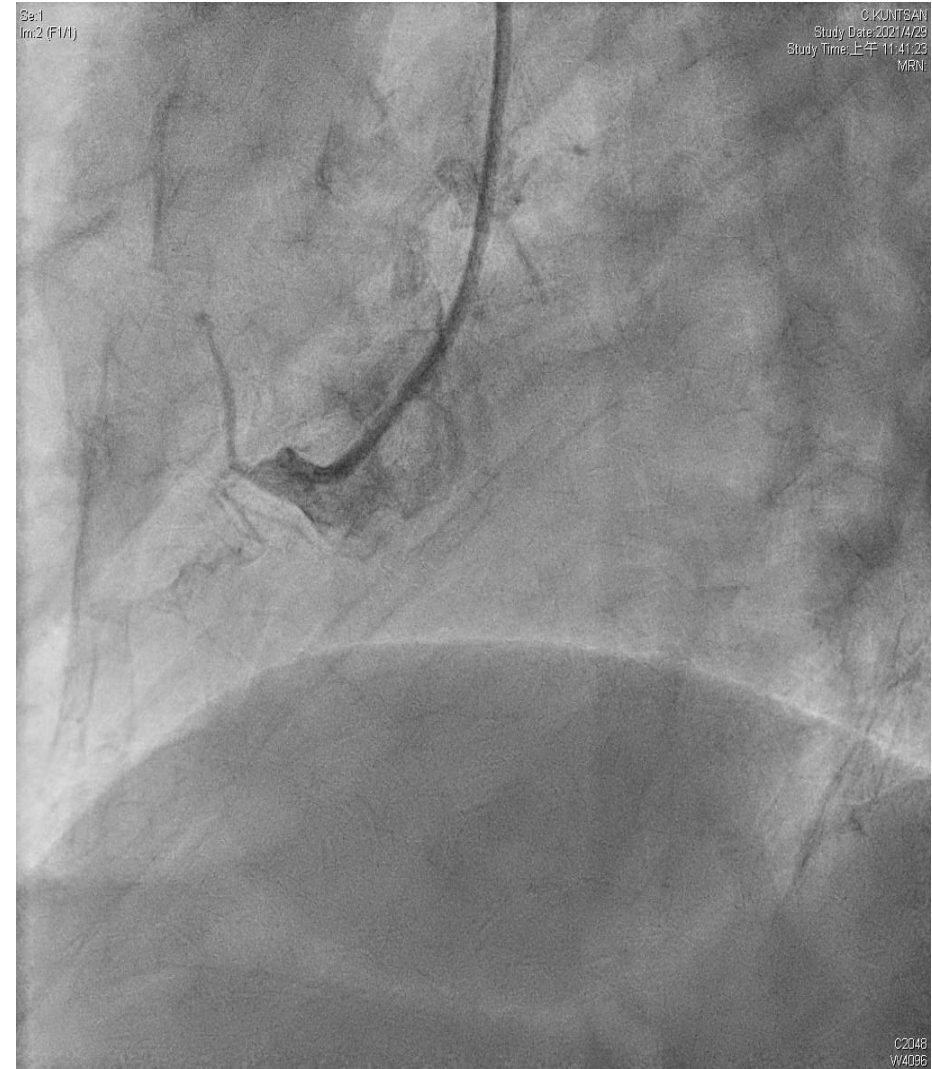


# TTT2023-Live Demo case 6

## 2023/1/8

- Name: 鄭X讚
- 79 y/o male
- History:
  - 2021-8 : DES to OM1 and d-LAD
  - LVEF:46%(2023/1)
- Target lesion: RCA CTO
- Strategy: Consider ADR



- Bilateral radial approach
- LCA: 7Fr EBU 3.75
- RCA: 7Fr SAL1 with side hole
- Try antegrade microchannel tracking with XT-A/Gaia 1st/Gaia 2nd/Gaia 3rd/M6/CP12 support by finecross and sasuke but still in suboptimal space
- Dilate suboptimal lumen with tornus 88 and Turnpike GOLD but cannot wire suboptimal space to near true lumen
- abort the procedure due to prolong procedure time.

